



## Effects of Shockwave Therapy Versus Mobilizing Exercise in Frozen Shoulder Patients

Mariam Mousa Soliman Abd El Hafiz<sup>1</sup>, Mohamed Azzazy<sup>1</sup>, Omar AbdElsamad Gazia<sup>2</sup>

1- Environmental Studies and Research Institute; university of Sadat City, Egypt.

2- Faculty of Therapy - Kafrelsheikh University, Egypt.

### Abstract

There are a few physical therapy research available for effect of shockwave versus mobilizing exercises in frozen shoulder patient. Therefore, the present study was done to investigate and compare the effect of Shockwave versus mobilizing exercises in frozen shoulder patient and answer the following question:

- Did Shockwave have a statistically significant effect in frozen shoulder patient?
- Did mobilizing exercises have a statistically significant effect in frozen shoulder patient? Are there any statistically significant differences between effects of shockwave versus mobilizing exercises in frozen shoulder patients?

The results obtained from the current study and the discussion that followed it was concluded that: it is more efficient to apply Shockwave therapy rather than mobilization in frozen shoulder patients even if both produce an effect in pain and range of motion. Depending on the findings of this study, it is recommended to use Shockwave therapy in frozen shoulder patients.

**Key words:** shockwave -frozen shoulder- Statistic

### Introduction

Adhesive capsulitis is a poorly understood musculoskeletal condition that can be disabling. Adhesive capsulitis is diagnosed by numerous physical characteristics including a thickening of the synovial capsule, adhesions within the subacromial or subdeltoid bursa, adhesions to the biceps tendon, and/or obliteration of the axillary fold secondary to adhesions. Since Duplay initially described a case report of adhesive capsulitis almost 130 years ago, this condition remains an enigmatic shoulder disorder that causes pain and restricted ROM at the glenohumeral joint (Healing, 2018b; Hoffmeister, 2016; Kvarstein, 2015; Radovanovic, 2013; Yeung, 2017).

The typical patient that develops adhesive capsulitis in 5th to 7th decade of life. There is generally no preference for handedness and adhesive capsulitis rarely occurs simultaneously bilaterally. However, others have reported that it can occur sequentially bilaterally in up to 40–50% of patients. Adhesive capsulitis is commonly

associated with other systemic and nonsystemic conditions. (Ewald, 2011; Healing, 2018b; Hsu, et al., 2011; Jain et al., 2014; Neviaser & Hannafin, 2010; Neviaser & Neviaser, 2011; Radovanovic, 2013; Seth, 2014).

The treatment of adhesive capsulitis involves many types of operative and non-operative therapies that include many physical therapy treatments. Only a few scientific reviews of frozen shoulder treatments have been published, but they suffer badly from the “garbage in, garbage out” problem: there’s not enough good quality research to review. And so there’s a strong theme in their conclusions: no one really knows what works yet, and most of the better evidence we do have is either unimpressive or outright disappointing. Despite over a hundred years of treating this condition the definition, diagnosis, pathology and most efficacious treatments are still largely unclear (Health & Education, 1999; Hsu et al., 2011; Jain et al., 2014; Kvarstein, 2015; Neviaser & Hannafin, 2010; Niel-Asher, 2002).

### **Statement of the Problem**

Because there were few physical therapy research available for effect of shockwave versus Mobilizing exercises in frozen shoulder patient, so this study was done to answer the following question:

- Did Shockwave have a statistically significant effect in frozen shoulder patient?
- Did mobilizing exercises have a statistically significant effect in frozen shoulder patient?

Are there any statistically significant differences between effects of shockwave versus mobilizing exercises in frozen shoulder patients?

### **Purpose of the Study**

The purpose of this study is to investigate and compare the effect of Shockwave versus Mobilizing exercises in frozen shoulder patient.

### **Significance of the Study**

Adhesive capsulitis has an incidence of 3–5% in the general population and up to 20% in those with diabetes. This disorder is one of the most common musculoskeletal problems seen in orthopedics. Although some have described adhesive capsulitis as a self-limiting disorder that resolves in 1–3 years, other studies report ranges of between 20 and 50% of patients with adhesive caspulisitis which suffer long-term ROM deficits that may last up to 10 years (Loeffler et al., 2011; McKenzie & Richardson, 2018).

The typical patient that develops adhesive capsulitis in 5th to 7th decade of life. There is generally no preference for handedness and adhesive capsulitis rarely occurs simultaneously bilaterally. However, others have reported that it can occur sequentially bilaterally in up to 40–50% of patients. Adhesive capsulitis is commonly associated with other systemic and nonsystemic conditions. By far the most common is the co-morbid condition of diabetes mellitus, with an incidence of 10–36%. (Chan et al., 2017; Chokkalingam et al., 2017).

## **Definition of Terms**

The following terms are defined for the clear understanding of the terminology that was used in the study:

### **Adhesive capsulitis**

Adhesive capsulitis (also known as frozen shoulder) is a painful and disabling disorder of unclear cause in which the shoulder capsule, the connective tissue surrounding the glenohumeral joint of the shoulder, becomes inflamed and stiff, greatly restricting motion and causing chronic pain (Aune, 2010; Barton, 2005; MacKenzie et al., 2003; Niel-Asher, 2002).

### **Extracorporeal shockwave therapy**

ESWT uses biphasic acoustic energy that goes from positive high peak pressures (10-100 MPa megapascals-MPa-for Focused F-ESWT; 0.1-1 MPa for Radial R-ESWT) to negative phase ( 10 MPa); short rise times (10-100 ns for F-ESWT; 0.5-1 ms for R-ESWT), short duration (0.2-0.5 ms for F-ESWT; 0.2-0.5 ms for R-ESWT)

(Gleitz and Hornig, 2012).

### **Anatomy and biomechanics:**

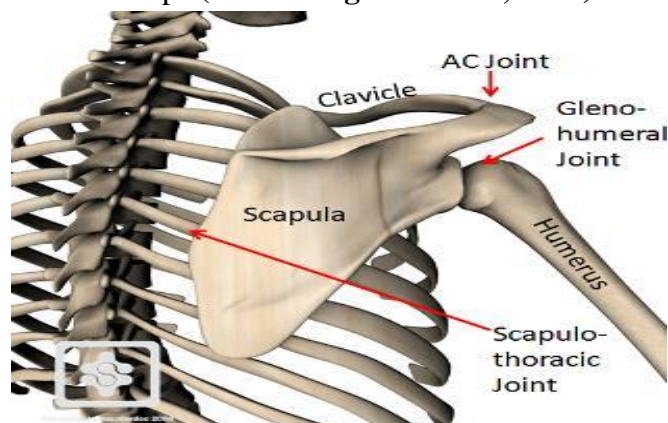
#### ***Glenohumeral joint anatomy***

The shoulder complex has the greatest mobility of all joints. On one hand, this mobility is because of little bony congruity of its articulating surfaces. The joints of the shoulder complex have to rely on adjacent ligaments and muscles to provide stability. Consequently, they are susceptible to injury and degeneration. On the other hand, the shoulder complex is composed of the scapulothoracic articulation and the glenohumeral joint to share the overall motion and increase its range. This composition allows the involved muscles to work in the most efficient part of their length-tension curve and the glenoid to be placed underneath the humeral head to bear some weight of the arm (Abrahams, 2009; Abrahams et al., 2003).

#### **Glenoid**

Inferior to the acromion, the flat scapula thickens to form the glenoid. The spin glenoid notch separates the base of the acromion from the glenoid. Its slightly concave surface is shaped like an inverted comma with an anterior incision, and the radius of curvature is larger than that of the humerus. The total surface area is three to four times smaller than that of the humerus. The central portion of the glenoid shows frequently an area of thinned cartilage. The glenoid faces laterally, being 10° to 15° superiorly tilted relative to the medial border of the scapula. Relative to the plane of the scapula, the glenoid surface is nearly perpendicular: retroversion of an average of 7.4° with an incidence of 75% or anteversion of an average of 2° to 10° with an incidence of 25% were noted. On its superior tip, the supraglenoid tubercle is origin

of the long head of the biceps. On its inferior pole, the infraglenoid tubercle is the origin of the long head of the triceps (Armstrong & Murthi, 2016).



**Fig.(1): The two-dimensional orientation of glenoid with respect to the medial border and the plane of the scapula ( Armstrong & Murthi, 2016).**

### **Glenoid Labarum**

The glenoid labarum is a ring of triangular shape in section overlying the peripheral circumference of the glenoid with its free rim projecting into the joint. It consists of dense fibrous tissue. Its base is attached to the margin of the glenoid fossa by fibrocartilage and fibrous bone. It is attached to the glenohumeral ligaments and blends superiorly with the origin of the long head of the biceps tendon at the supraglenoid tubercle. Its function is to increase congruity, generating a suction effect and enhancing stability of the glenohumeral joint (Atlas, 2009; Bain et al., 2015).

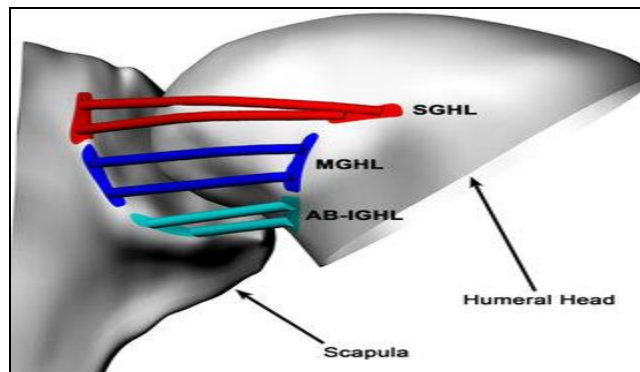
### **Glenohumeral Joint Capsule**

The capsule of the glenohumeral joint has a large volume of normally about 10 to 15 mL and twice the surface area of the humeral head. On the inside, it is covered with synovium; on the outside, rotator cuff tendons protect the capsule on all but the inferior aspect. The tendons of the subscapularis and supraspinatus are even fused with the capsule close to their insertion. The capsule begins at the border of the labarum, is attached to its outer surface, and is anchored onto the bone of the glenoid neck. It extends superiorly to the coracoid process and in varying length along the biceps tendon into the intertubercular groove. It inserts into the anatomic neck close to the cartilage of the humeral head and with some distance inferiorly to form the axillary recess. Apart from the outlet for the biceps tendon, the capsule has a gap for the subscapular recess anteriorly (Bozkurt & Açar, 2017; Chung, 2005).

Histologically the capsule is composed of three layers: an outer and an inner layer with fibres running in the frontal plane from the glenoid to humerus and a middle layer with fibres running in the sagittal plane. The glenohumeral ligaments reinforce the joint capsule. They are an abrupt thickening of the inner layer with organized collagen bundles in the frontal plane. A thickening of middle layer reinforces the axillary pouch. Contrary to the anterior joint capsule, the posterior is quite thin (Culham, Peat, & Therapy, 1993; Devi, 2018).

### **Glenohumeral Ligaments**

The coracohumeral ligament originates from the base and lateral border of the coracoid process and runs transversely to the greater tuberosity. Its anterior border is distinct medially and merges laterally, whereas its posterior border is indistinct. It is a primary restraint to the long head of the biceps tendon (Di Giacomo et al., 2008; Dutton, 2008).



**Fig 2** SGHL = superior glenohumeral ligament, MGHL = middle glenohumeral ligament; PC = posterior capsule; IGHL = inferior glenohumeral ligament complex; AB = anterior band (Elser et al., 2011; Franklyn-Miller, Falvey, McCrory, & Brukner, 2010).

The transverse humeral ligament is the roof of the proximal end of the bicipital groove and acts as the retinaculum for the long head of the biceps tendon. It is made of transverse fibres of the capsule (Gartsman & Edwards, 2008).

Although constant in presence, the superior glenohumeral ligament is variable in size and origin. It arises from the anterior labrum, sometimes as far superior as the long head of the biceps tendon and sometimes as far inferior as the middle glenohumeral ligament or in between (Grine, 2004).

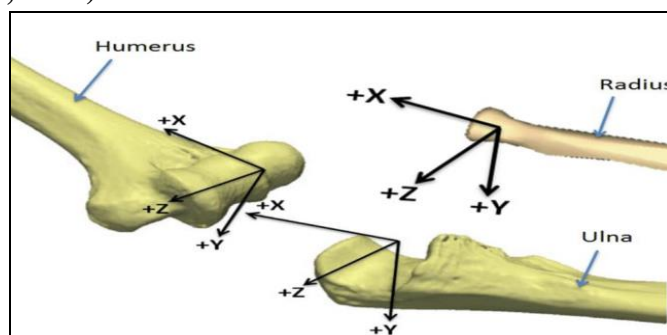
The middle glenohumeral ligament shows the largest variation in diameter. It can be as thin as the capsule or as thick as the subscapularis tendon. It originates from the anterior labrum or glenoid neck to insert into the lesser tuberosity underneath the subscapularis tendon with which it is mingled (Haas, 2010).

The inferior glenohumeral ligament is thicker than the rest of the capsule, although variable in size and attachment site. Its structure resembles a hammock consisting of a prominent anterior band, a posterior band, and the axillary pouch in between. Looking at the glenoid being divided like a clock, the anterior band originates from the glenoid or labrum from the 2 to 4 o'clock position and the posterior band from the 7 to 9 o'clock position. It inserts into the anatomic neck of the humerus inferior to the cartilage in a U or V shaped fashion (Hallam, 2008).

### **Humeral Head**

The articular surface has an ovoid shape facing medially, superiorly, and posteriorly. The humeral head is inclined about 130° relative to the shaft with 30° of retrotorsion relative to the condyles of the elbow. The articular surface of the humeral head forms almost a true sphere. The margin is tilted 45° relative to the humeral shaft.

In contrast to the glenoid, the central portion of its hyaline cartilage is the thickest (Hansen & Kennelly, 2018).



**Fig 3 The three-dimensional orientation of the articular surface of the humeral head, with respect to the bicondylar axis of the elbow (Hansen & Kennelly, 2018).**

The anterior border of the articular surface is the lesser tuberosity, and its lateral border is the greater tuberosity with the intertubercular groove in between. Together with the medial surface of the surgical neck, they are sites for a ring of tendinous and ligamentous attachments around the articular surface. This ring functions to stabilize the joint by centralizing the humeral head while tightening around the prominent articular surface (Hodge & Education, 2006; Iazzetti & Rigutti, 2005).

The intertubercular groove lies 30° medial 70° or 9 mm anterior to the central axis of the articular surface. It is bordered by the lesser tuberosity anteriorly and by the greater tuberosity posteriorly. The transverse ligament bridges the intertubercular groove proximally to act as a retinaculum for the long head of the biceps tendon. Distally the subscapularis tendon inserting onto the lesser tuberosity forms the floor of the sheath. The supraspinatus tendon inserting onto the greater tuberosity forms its roof. The depth of the intertubercular groove seems to play a role in the pathogenesis of long head of the biceps tendinitis by more or less exposing the tendon to an impingement process (Jarmey, 2004; Johnson & research, 1987).

There are three facets on the greater tuberosity: the superior, the middle, and the inferior. The supraspinatus muscle inserts onto the superior facet and the superior half of the middle facet. Anterior fibers of the supraspinatus tendon mingle with the subscapularis tendon fibers. Posteriorly the infraspinatus tendon attaches to the middle facet, covering the posterior border of the supraspinatus tendon. The teres minor tendon inserts onto the inferior facet (Kapit & Elson, 2002; Logan et al., 2004).

## Scapulohumeral Muscles

### Supraspinatus.

The supraspinatus muscle takes fleshy origin in the supraspinatus fossa to have a tendinous insertion onto the greater tuberosity. The muscle belly has a fusiform shape with a thick tendinous core, the intramuscular tendon, located in the anterior third. Approximately 70% of the muscle fibers attach to the intramuscular tendon, whereas 30% attach directly to the extramuscular tendon. This muscle is categorized as a

circumpennate muscle. The superficial tendon fibers run longitudinally, whereas the deep ones run obliquely to mingle with adjacent muscles and create a tendinous ring. The supraspinatus is part of the force couple to stabilize the glenohumeral joint by compression and initializes elevation. Elevation in case of supraspinatus paralysis requires more deltoid force, but the other rotator cuff muscles are still able to stabilize the humeral head sufficiently for full range of motion. The suprascapular nerve (C4–6) supplies innervation (**Marieb, 2004; Moreno, 2016**).

### **Infraspinatus.**

The infraspinatus muscle takes fleshy origin in the infraspinatus fossa and scapular spine to insert with a flat tendon onto the middle facet of the greater tuberosity. It is a circumpennate muscle with an intramuscular tendon located in the centre of the muscle belly. The infraspinatus muscle stabilizes the glenohumeral joint by resisting posterior and superior translation and generates 60% of the overall external rotation force. The suprascapular nerve (C4–6) supplies innervation (**Morton et al., 2018; O'Brien et al., 1990**).

### **Teres Minor.**

Origin of the teres minor muscle is the lateral border of the scapula and the infraspinatus fascia, and its fleshy insertion is located inferior to the infraspinatus muscle on the inferior facet of the greater tuberosity. Similar to the infraspinatus, this is a circumpennate muscle with a single intramuscular tendon located in the center of the muscle belly. The teres minor muscle acts as stabilizer of the glenohumeral joint by resisting posterior and superior translation and generates 45% of the total external rotation force. The posterior branch of the axillary nerve (C5–6) supplies innervation (**Patton & Thibodeau, 2010; Porterfield & DeRosa, 2004**).

### **Subscapularis.**

The subscapularis muscle takes fleshy origin in the subscapularis fossa and inserts onto the lesser tuberosity. Its tendinous bands are interspersed evenly in the medial portion of the muscle to condense laterally into a flat tendon in the superior two thirds, whereas the inferior third remains muscular. This muscle with multiple intramuscular tendons is a multicircumpennate muscle. The subscapularis sends fibers of its tendinous insertion across the intertubercular groove to form the floor of the bicipital sheath. As the only component of the anterior rotator cuff, it stabilizes actively the glenohumeral joint by resisting anterior and inferior translation and acts as a strong internal rotator. It is considered to be a passive stabilizer too, because of the dense collagen structure of its tendon and its fusion with the middle and inferior glenohumeral ligament. Two branches of the subscapular nerve (C5–8) for the superior and inferior portion of the muscle supply innervation (**Rockwood, 2009; Science, 2009**).

### **Deltoid.**

The deltoid muscle is composed of the clavicular part originating from the lateral clavicle, the acromial part from the acromion, and the spinal part from the scapular spine. Their common insertion is the deltoid tubercle on the humerus. The deltoid is the most important abductor of the glenohumeral joint. Although the acromial portion is the strongest one and starts the movement, the clavicular and spinal portions participate at higher degrees of abduction. Conversely, in low degrees of abduction, the medial fibres of the anterior and posterior portions can take part in adduction of the arm. Additionally, the anterior portion affects flexion and the posterior portion extension. Paralysis of the deltoid results mainly in 50% loss of abduction strength. The axillary nerve (C4–5) innervates the deltoid (**Seiger, 2002, 2004**).

### **Teres Major.**

The teres major originates from the posterior surface of the inferior angle of the scapula to take a tendinous insertion on the medial margin of the intertubercular groove. On its way to the humerus, it takes a 180° spiral course with the posterior fibres inserting anteriorly. Its functions are internal rotation, adduction, and extension of the humerus. The subscapular nerve (C5–7) supplies innervation (**Seikel et al., 2005; Sethi, 2005**).

### **Biceps.**

The long head of the biceps muscle has its origin at the supraglenoid tubercle. Ensheathed by the synovial membrane, it runs intra-articularly on top of the humeral head to exit the joint capsule through the intertubercular groove. The short head of the biceps originates from the coracoid process. Both heads have a common insertion onto the tuberosity of the radius laterally and onto the ulnar fascia of the forearm medially. Although it acts as a stabilizer of the humeral head, its main function is to effect elbow flexion and forearm supination. The biceps muscle is innervated by the musculocutaneous nerve (C5–6) (**Shamley et al., 2014; Trumble et al., 2006**).

### **- Triceps.**

The long head of the triceps originates from the infraglenoid tubercle and the inferior labrum to insert in common with both other heads onto the olecranon. The long head participates in extension and adduction of the glenohumeral joint, whereas the main function of the whole muscle is extension of the elbow joint. The radial nerve (C6–8) supplies innervation (**Kapit & Elson, 2002; Rockwood, 2009; Vella, 2006**).

### **Coracobrachialis.**

The coracobrachialis muscle originates in common with the short head of the biceps on the coracoid process to insert onto the anteromedial surface of the central humerus. It participates in flexion and adduction of the glenohumeral joint. The musculocutaneous nerve enters the coracobrachialis muscle between 2 and more than 5 cm inferior to the tip of the coracoid process to innervate it (**Culham et al., 1993; Di Giacomo et al., 2008; Franklyn-Miller et al., 2010; Haas, 2010; Hansen & Kennelly, 2018; Moreno, 2016; Porterfield & DeRosa, 2004**).



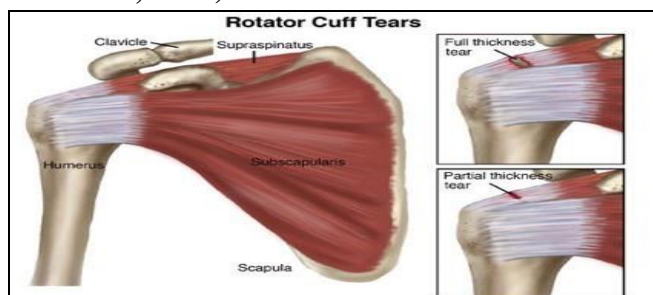
## **Glenohumeral joint biomechanics.**

### **Motion**

The humeral head and the glenoid articular surface show a high degree of conformity. The humeral head is believed to be more convex in the anterior-posterior direction than in the superior-inferior direction. Some authors measured the sphericity of the humeral head using stereophotogrammetry, however, and concluded that the articular surface of the humeral head could be approximated by a sphere with small deviations of less than 1% of the radius. The difference between the two diameters of the humeral head is less than 1 mm in 88.2% of the tested specimens. The motion of the glenohumeral joint is basically ball-and-socket in nature (**Berliner et al., 2015; Patel et al., 2012**).

During active and passive arm elevation, the superior-inferior translation of the humeral head is only 0.3 to 0.35 mm in normal shoulders. Anterior-posterior translation is substantially larger. The head translates anteriorly 3.8 mm on average during flexion, translates posteriorly 4.9 mm during extension, and translates 4 mm during horizontal extension. Larger translations in the anterior-posterior direction than in the superior-inferior direction occur as a result of the bony configuration of the glenoid because it is more concave in the superior-inferior direction (radius of curvature =  $32.2 \pm 7.6$  mm) than in the anterior-posterior direction (radius of curvature =  $40.6 \pm 14$  mm) (**Entezari et al., 2012; Merolla et al., 2015**).

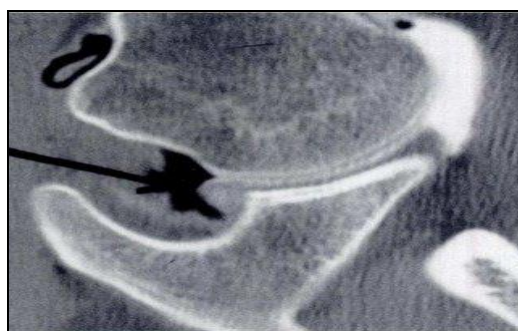Glenohumeral kinematics is affected by various pathologic conditions of the shoulder. Partial-thickness or full-thickness rotator cuff tears typically are associated with superior migration of the humeral head during arm elevation. This migration is caused by the imbalance between the deltoid and the insufficient cuff muscles. Even with the intact cuff tendons, muscle fatigue might cause superior shift of the humeral head. In shoulders with anterior instability, the humeral head is located more anteriorly with the arm in horizontal extension and external rotation. In stiff shoulder joints, the humeral head moves upward during the first degrees of arm elevation (**Degen et al., 2013; Herrmann, 2016**).



**Partial- or full-thickness rotator cuff tears typically are associated with superior migration of the humeral head during arm elevation, caused by the imbalance between the deltoid and the insufficient cuff muscles (Degen et al., 2013; Herrmann, 2016).**

In a spatial motion analysis, the maximal glenohumeral elevation was obtained in a plane 23° anterior to the scapular plane with the arm in 35° of external rotation. The maximal humerothoracic elevation is achieved in a plane 4° posterior to the scapular plane. This discrepancy seems to result from a difference between isolated motion of the glenohumeral joint and combined motion of the glenohumeral and scapulothoracic joints. External rotation at the glenohumeral joint during arm elevation is necessary to clear the greater tuberosity from the coracoacromial arch and to accommodate the retroverted articular surface in an optimal position for glenoid contact. With the arm in external rotation, a larger portion of the articular surfaces are in contact (**Felstead et al., 2017; Limb & Textbook, 2014**).

Translation of the humeral head reproducibly accompanied passive movements of the glenohumeral joint. The humeral head translates anteriorly with the arm in flexion and posteriorly with the arm in extension. This forced translation is thought to be induced by the tightening of the capsuloligamentous structures during motion. Excessive tightness of the anterior capsule after anterior capsulorrhaphy leads to posterior subluxation (**Ahmad et al., 2014; Patel et al., 2012; Shamley et al., 2014; Shenoy, 2017**).



**Fig 4 Translation of the humeral head accompanies even passive movements of the glenohumeral joint. This forced translation is induced by the tightening of the capsuloligamentous structures during motion. Excessive tightness of the anterior capsule following anterior capsulorrhaphy leads to posterior subluxation. P = displacing force (Ahmad et al., 2014; Patel et al., 2012; Shamley et al., 2014; Shenoy, 2017).**

### **Stability**

#### **Ligaments.**

Ligaments are sturdy, band-like structures that connect bones to other bones and are important for stability. Once stretched, they tend to stay stretched and if stretched too far, they can tear. There are several important ligaments about the shoulder girdle. Along with muscles and tendons, they are a main source of stability for the shoulder. Shoulder ligaments also form the joint capsule that surround the glenohumeral joint. (**Abrahams, 2009; Abrahams et al., 2003; Bain et al., 2015; Di Giacomo et al., 2008; Hansen & Kennelly, 2018**)

The superior glenohumeral ligament is an anterior stabilizer and an inferior stabilizer in the hanging arm position. The major role of the middle glenohumeral

ligament is anterior stabilization with the arm in adduction up to 30° to 45° of abduction. This function is apparent in 90° of abduction with the arm in neutral rotation but not in external rotation. It is also an inferior stabilizer with the arm in adduction (Ahrens, 2015; Merolla et al., 2015; Reddy, 2015; Shamley et al., 2014).

The inferior glenohumeral ligament is the most important anterior stabilizer with the arm in abduction and external rotation, the position of anterior dislocation. The function is by its anterior band and the axillary pouch but not by its posterior band. The posterior band is a posterior stabilizer with the arm in flexion and internal rotation or in 90° of abduction. With abduction and external rotation, the anterior band fans out to support the humeral head, whereas the posterior band becomes cordlike. The opposite happens in internal rotation (Ahmad et al., 2014; Alibazi et al., 2015; Merolla et al., 2015).

The coracohumeral ligament (CHL) is known to be an inferior stabilizer with the arm in adduction. It functions as an inferior stabilizer and tightens in external rotation. The CHL also stabilizes the head in the superior direction but to a minor degree (Ahrens, 2015; Erickson et al., 2014; Maria et al., 2017).

A rotator cuff interval lesion is clinically apparent as inferior instability with the arm in internal rotation but not in external rotation. The rotator interval capsule indirectly stabilizes the shoulder inferiorly by means of maintaining the negative intra-articular pressure. In external rotation, the CHL prevented inferior instability even after the interval capsule was sectioned. The rotator interval capsule also provides posterior stability (Charalambous, 2019; Entezari et al., 2012; Shamley et al., 2014; Veeger & Gasparutto, 2018).

### **Glenoid Concavity.**

The glenoid fossa has a concavity, which centers the humeral head on the glenoid. It is deeper in the superior-inferior direction than in the anterior-posterior direction. The humeral head is more stable in the superior-inferior direction than in the anterior-posterior direction. When the head is compressed onto the glenoid fossa, the force necessary to dislocate the head is approximately 60% of the compressive force (stability ratio) in the superior-inferior directions and 35% in the anterior-posterior directions (Ahmad et al., 2014; Elkousy et al., 2011; Merolla et al., 2015; Mirhadizadeh, 2018; Shamley et al., 2014).

### **Labrum.**

The function of the labrum is to increase the stability of the humeral head on the glenoid socket by increasing the depth of its cavity. After removal of the labrum, the stability ratio decreases by 20% on average (Ahrens, 2015; Bumbea et al., 2010; Davenport, 2018; Felstead et al., 2017; Maria et al., 2017; Merolla et al., 2015; Shamley et al., 2014).

### **Scapular Inclination.**

Basmajian and Bazant<sup>4</sup> noticed that the shoulder was unstable inferiorly when the arm was in abduction, but it was stabilized with the arm in adduction. They thought that in adduction, the superior capsuloligamentous structures became tight because of the slope of the glenoid fossa, which prevented inferior translation of the humeral head. In shoulders with multidirectional instability, the scapula is less abducted during arm elevation than in healthy shoulders. Inferior instability as part of multidirectional instability can thus be explained by the lack of the stabilizing effect of scapular inclination (Ahmad et al., 2014; Alibazi et al., 2015; Elser et al., 2011; Herrmann, 2016; Levy & Narvani, 2011; Merolla et al., 2015; Scheiderer & Lacheta, 2017; Shamley et al., 2014). Clinical phases

Adhesive capsulitis presentation is generally broken into three distinct stages. The first stage that is described is called the freezing or painful stage. Patients may not present during this stage because they think that eventually the pain will resolve if self-treated. As the symptoms progress, pain worsens and both active and passive ROM becomes more restricted, eventually resulting in the patient seeking medical consultation. This phase typically lasts between 3 and 9 months and is characterized by an acute synovitis of the glenohumeral joint (**Kim, Yoo, Kwak, Jeong, & Kim, 2017; Wang et al., 2017**).

Most patients will progress to the second stage, the frozen or transitional stage. During this stage shoulder pain does not necessarily worsen. Because of pain at end ROM, use of the arm may be limited causing muscular disuse. The frozen stage lasts anywhere 4 to 12 months. The common capsular pattern of limitation has historically been described as diminishing motions with external shoulder rotation being the most limited, followed closely by shoulder flexion, and internal rotation. There eventually becomes a point in the frozen stage that pain does not occur at the end of ROM (**Pietrzak, 2016; Sun et al., 2016**).

The third stage begins when ROM begins to improve. This 3rd stage is termed the thawing stage. This stage lasts anywhere from 12 to 42 months and is defined by a gradual return of shoulder mobility (**Prestgaard et al., 2015; Theodorides et al., 2014**).

### **Pathology**

Pain associated with adhesive capsulitis can cause a limitation or selective immobilization of the painful shoulder. Prolonged immobilization of a joint has been shown to cause several detrimental pathophysiologic findings including: decreased collagen length, fibrofatty infiltration into the capsular recess, ligament atrophy resulting in decreased stress absorption, collagen band bridging across recesses, random collagen production, and altered sarcomere number in muscle tissue (**Barton, 2005; Davies, 2006; Varcin, 2013**).

### **Evaluation**

The evaluation of adhesive capsulitis starts with a thorough shoulder history. Inciting events such as mild trauma are often given in relation to the shoulder pain.

This may be something very trivial, and in fact may not be related to the process, but the patient may recall something that is attributed to starting the process. Adhesive capsulitis often involves the non-dominant extremity. This is because it is easier to protect and not use the extremity because it is painful and the dominant extremity can do the work. When the extremity is held close to the body, often to “protect it”, the process can then proceed unchecked. This becomes even more apparent when passive ROM is accompanied by an unusual amount of pain and guarding. The entity describing a slow onset of pain was discussed, felt near the insertion of the deltoid, inability to sleep on the affected side, and restriction in both active and passive elevation as well as external rotation, yet with normal radiologic appearance. Without degenerative joint disease on radiographs, this clinical picture suggests the diagnosis of adhesive capsulitis (**Aune, 2010; Central, 2019b; Davies, 2006; Ims, 2018**).

The physical examination is marked by the loss of both passive and active range of motion. This motion may also be painful as the capsule reaches its stretching point. Examination tests for other shoulder abnormalities can also be positive. Testing for impingement may be positive with a Hawkins’s or Neer sign; however, the pain is likely from the intrinsic process of impingement or capsular stretch rather than from adhesive capsulitis (**Health & Education, 1999; Mohamed, 2007; Sun et al., 2016; Varcin, 2013**).

The diagnosis of adhesive capsulitis is often one of exclusion. Early in the disease process adhesive capsulitis may clinically appear similar to other shoulder conditions such as major trauma, rotator cuff tear, rotator cuff contusion, labral tear, bone contusion, subacromial bursitis, cervical or peripheral neuropathy. Additionally, a history of a previous surgical procedure can lead to shoulder stiffness. If a history of these other pathologies are negative and if radiographs do not demonstrate osteoarthritis, then the diagnosis can be given (**Central, 2019c; Harris et al., 2013; Seth, 2014; Sun et al., 2016; Walmsley et al., 2017**).

A screening radiograph of the shoulder is imperative to diagnose adhesive capsulitis. This rules out other possible diagnosis of loss of ROM that include osteoarthritis, or chronic anterior or posterior dislocation (**Central, 2019b; Chiang & Dugan, 2016; Kim et al., 2017; Niel-Asher, 2002; Prestgaard et al., 2015; Yeung, 2017**).

### **Non-operative treatments:**

#### **Anti-inflammatories**

Treatment of adhesive capsulitis often involves the use of anti-inflammatories, or corticosteroids. NSAIDs may be used during any phase as an attempt to relieve symptoms. There are no well done studies to indicate that NSAIDs change the natural history of adhesive capsulitis. There is a paucity of literature that even would support the use of NSAIDS for this diagnosis. However, NSAIDS are not only anti-inflammatories, they are analgesics and are a reasonable first choice for treatment (**Barton, 2005; Davies, 2006; Hoffmeister, 2016; Kvarstein, 2015**).

### **Intra-articular corticosteroid injections**

Although high-quality randomized studies of corticosteroid injection for treatment of adhesive capsulitis have not been done, there is some evidence to indicate there is a short-term benefit with their use. Given the low likelihood of complications with this approach, the use of either a subacromial injection or glenohumeral injection should be considered. One limitation to using this form of treatment comes upon recent evidence that injections performed blindly may be inaccurate in approximately 60% of cases. Better clinical outcome is found with greater accuracy. This problem may be overcome with the use of ultrasound guided joint injection (**Barton, 2005; Central, 2019c; Healing, 2018b; Ims, 2018**).

### **Capsular distension injections**

This method of treatment has been described for patients under local anesthesia. The joint is injected to its limits with local anesthetic to attempt to stretch the capsule. This technique is often poorly tolerated because of pain that is experienced during the process as the entire shoulder is not anesthetized from the intra-articular injection (**Davies, 2006; Hsu et al., 2011; mohamed, 2007; Niel-Asher, 2002; Radovanovic, 2013**).

### **Surgical treatment**

The treatment of adhesive capsulitis should lead to the operating room only after a concerted effort at conservative management has failed. There is not a discrete timeline to head to surgery. As a general rule patients should have participated in some form of therapy for at least 2 months, and shown no progress. Patients should feel they are not making progress and have significant pain and limitations of occupation, recreation, or sleep to proceed with surgical intervention (**Ims, 2018; Kvarstein, 2015; Neviasser & Hannafin, 2010; Neviasser & Neviasser, 2011; Seth, 2014; Varcin, 2013**).

### **Conclusions**

The results obtained from the current study and the discussion that followed it was concluded that: it is more efficient to apply Shockwave therapy rather than mobilization in frozen shoulder patients even if both produce an effect in pain and range of motion.

### **Implementations**

Depending on the findings of this study, it is recommended to use Shockwave therapy in frozen shoulder patients.

### **References**

- Abrahams, P. H. (2009). *Atlas of Human Anatomy*: Amber Books.
- Abrahams, P. H., McMinn, R. M. H., Marks, S. C., & Hutchings, R. T. (2003). *McMinn's color atlas of human anatomy*: Mosby.
- Ahmad, C. S., Dyrzka, M. D., & Kwon, D. H. (2014). *Biomechanics of the Shoulder*. In *Shoulder Arthroscopy* (pp. 17-30): Springer.

- Ahrens, P. (2015). Biomechanics of the Shoulder. In *Fractures of the Proximal Humerus* (pp. 19-24): Springer.
- Al Shehri A, Almureef SS, Khan S, Shamsi S. Efficacy of Maitland Mobilization in Frozen Shoulder. *Europ J Biomed Pharma Sci.* 2018;5(12):22-27.
- Alibazi, R. J., Moghadam, A. N., Zarrabi, V., Bakhshi, E., & Nakhaei, N. J. R. (2015). The effect of muscle fatigue on normal biomechanics of shoulder girdle: a systematic review of the literature. 16(3).
- Alvarez D.J., P.G. Rockwell, Trigger points: diagnosis and management, *Am. Fam. Physician* 65 (2002) 653e660.
- Armstrong, A. D., & Murthi, A. M. (2016). *Anatomic Shoulder Arthroplasty: Strategies for Clinical Management*: Springer International Publishing.
- Atlas, S. (2009). *Atlas of Anatomy*: h.f.ullmann.
- Aune, R. (2010). *Effects of a Physical Therapy Program for a Patient with Shoulder Adhesive Capsulitis*: University of North Dakota.
- Bain, G. I., Itoi, E., Di Giacomo, G., & Sugaya, H. (2015). *Normal and Pathological Anatomy of the Shoulder*: Springer Berlin Heidelberg.
- Barton, G. (2005). *The Frozen Shoulder*: Universal Publishing Solutions Online, Limited (UPSO).
- Berliner, J. L., Regalado-Magdos, A., Ma, C. B., Feeley, B. T. & surgery, e. (2015). Biomechanics of reverse total shoulder arthroplasty. 24(1), 150-160.
- Bozkurt, M., & Açar, H. İ. (2017). *Clinical Anatomy of the Shoulder: An Atlas*: Springer International Publishing.
- Bumbea, A. M., Trăistaru, R., Albu, C., Dumitrașcu, R. C., & Bumbea, B. Ș. (2010). The shoulder-anatomical and biomechanics aspects. 215.
- Carroll, D. (2009). *Treatment of a Bankart Lesion Repair with Adhesive Capsulitis: a Modified Protocol*: Sage Colleges.
- Carville S.F., S. Arendt-Nielsen, H. Bliddal, F. Blotman, J.C. Branco, D. Buskila, J.A. Da Silva, B. Danneskiold-samsøe, F. Dincer, C. Henriksson, E. Kosek, K. Longley, G.M. McCarthy, S. Perrot, M. Puszczewicz, P. Sarzi-Puttini, Silman, M. Spaeth, E.H. Choy, EULAR evidence-based recommendations for the management of fibromyalgia syndrome, *Ann. Rheum. Dis.* 67 (2008) 536e541.
- Çeliker, R.; Arslan, S. Comparison of the efficacy of local corticosteroid injection and physical therapy for the treatment of adhesive capsulitis. *Rheumatol. Int.* 2001, 21, 20–23.
- Central, H. (2019a). *Reversing Adhesive Capsulitis Naturally The Raw Vegan Plant-Based Detoxification & Regeneration Workbook for Healing Patients*: Raw Power.
- Central, H. (2019b). *Reversing Adhesive Capsulitis: Overcoming Cravings The Raw Vegan Plant-Based Detoxification & Regeneration Workbook for Healing Patients*: Raw Power.
- Central, H. (2019c). *Reversing Frozen Shoulder Naturally The Raw Vegan Plant-Based Detoxification & Regeneration Workbook for Healing Patients*: Raw Power.
- Chan, J. H., Ho, B. S., Alvi, H. M., Saltzman, M. D., Marra, G. J. J. o. s., & surgery, e. (2017). The relationship between the incidence of adhesive capsulitis and hemoglobin A1c. 26(10), 1834-1837.
- Charalambous, C. P. (2019). *Shoulder Biomechanics*. In *The Shoulder Made Easy* (pp. 45-67): Springer.
- Chiaia, T. A., Hannafin, J. A & Surgery, E. (2014). Adhesive capsulitis. 15(1), 2-7. Chiang, J., & Dugan, J. (2016). *Adhesive Capsulitis*: Lippincott Williams & Wilkins.

- Cho Y.S., S.J. Park, S.H. Jang, Y.C. Choi, J.H. Lee, J.S. Kim, Effects of combined treatment of extracorporeal shock wave therapy (ESWT) and stabilisation exercises on pain and functions of patients with myofascial pain syndrome, *J. Phys. Ther. Sci.* 24 (2012) 1319e1323.
- Cho, C.-H.; Bae, K.-C.; Kim, D.-H. Treatment Strategy for Frozen Shoulder. *Clin. Orthop. Surg.* 2019, 11, 249–257., Koh, K.H. Corticosteroid injection for adhesive capsulitis in primary care: A systematic review of randomised clinical trials. *Singap. Med. J.* 2016, 57, 646–657.
- Chokkalingam, M., Saradha, S., Navitha, A., Nayar, P. G. J. J. o. C., & Cardiology, P. (2017). Incidence and clinical profile of patients with frozen shoulder after cardiac surgery. *6(4)*, 142.
- Chung, K. W. (2005). *Gross Anatomy: Lippincott Williams & Willkins.*
- Cummings T.M., A.R. White, Needling therapies in the management of myofascial trigger point pain: a systematic review, *Arch. Phys. Med. Rehabil.* 82 (2001) 986e992.
- Davenport, A. J. (2018). *Ultrasound Study of Shoulder Biomechanics.* University of Oregon,
- Davies, C. (2006). *Frozen Shoulder Workbook: Trigger Point Therapy for Overcoming Pain & Regaining Range of Motion: New Harbinger Publications.*
- De R. Venancio A., F.G. Alencar, C. Zamperini, Different substances and dry-needling injections in patients with myofascial pain and headaches, *Cranio* 26 (2008) 96e103.
- Degen, R. M., Giles, J. W., Thompson, S. R., Litchfield, R. B., & Athwal, G. S. J. C. S. M. (2013). Biomechanics of complex shoulder instability. *32(4)*, 625-636.
- Devi, V. S. (2018). *Textbook of General Anatomy: with Systemic Anatomy, Radiological Anatomy, Medical Genetics: Jaypee Brothers, Medical Publishers Pvt. Limited.*
- Di Giacomo, G., Pouliart, N., Costantini, A., & de Vita, A. (2008). *Atlas of Functional Shoulder Anatomy: Springer Milan.*
- Dickerson, C. R. (2005). *A biomechanical analysis of shoulder loading and effort during load transfer tasks: University of Michigan.*
- Do Moon G, Lim JY, Da YK, Kim TH. Comparison of Maitland and Kaltenborn mobilization techniques for improving shoulder pain and range of motion in frozen shoulders. *J Phys Ther Sci.* 2015;27(5):1391-5.
- Dommerholt J., O. Mayoral del Moral, C. Grobli, Trigger point dry needling, *J. Man. Manip. Ther.* 14 (2006) 70e87.
- Du Prel, J.-B., Röhrig, B., Hommel, G., & Blettner, M. J. D. Ä. I. (2010). Choosing statistical tests: part 12 of a series on evaluation of scientific publications. *107(19)*, 343.
- Dutton, M. (2008). *Orthopaedic Examination, Evaluation, and Intervention: Second Edition: McGraw-Hill Education.*
- Eggers, J., Cil, A. J. S. I. P., *Diagnosis, Treatment, & Rehabilitation.* (2015). *Shoulder Anatomy and Biomechanics of the Rotator Interval.* 1-7.
- Elkousy, H., Gartsman, G., Labriola, J. J. Y. B. o. H., & -E-Book, U. L. S. (2011). *25 Shoulder: Biomechanics and Examination.* 2011(802), 189.
- Elser, F., Braun, S., Dewing, C. B., Giphart, J. E., Millett, P. J. J. A. T. J. o. A., & Surgery, R. (2011). Anatomy, function, injuries, and treatment of the long head of the biceps brachii tendon. *27(4)*, 581-592.
- Entezari, V., Della Croce, U., DeAngelis, J., Ramappa, A., Nazarian, A., Trechsel, B., research, j. (2012). Design and manufacture of a novel system to simulate the biomechanics of basic and pitching shoulder motion. *1(5)*, 78-85.
- Erickson, B. J. *Shoulder Throwing Biomechanics.*
- Ewald, A. J. (2011). Adhesive capsulitis: a review. *83(4)*, 417-422.



- Favejee, M., Huisstede, B., & Koes, B. J. B. j. o. s. m. (2011). Frozen shoulder: the effectiveness of conservative and surgical interventions—systematic review. 45(1), 49-56.
- Felstead, A. J., Ricketts, D. J. O., & Trauma. (2017). Biomechanics of the Shoulder and Elbow. 31(5), 300-305.
- Frankle, M., Marberry, S., & Pupello, D. (2015). Reverse Shoulder Arthroplasty: Biomechanics, Clinical Techniques, and Current Technologies: Springer International Publishing.
- Franklyn-Miller, A., Falvey, E., McCrory, P., & Brukner, P. (2010). Clinical Sports Anatomy: McGraw-Hill Education Australia.
- Gartsman, G. M., & Edwards, T. B. (2008). Shoulder Arthroplasty: Saunders/Elsevier.
- Ge H.Y., C. Fernandez-de-Las-Penas, S.W. Yue, Myofascial trigger points spontaneous electrical activity and its consequences for pain induction and propagation, Chin. Med. 6 (2011)
- Gerber L.H., J. Shah, W. Rosenberger, K. Armstrong, D. Turo, P. Otto, J. Heimur, N. Thaker, S. Sikdar, Dry needling alters trigger points in the upper trapezius muscle and reduces pain in subjects with chronic myofascial pain, PM R 7 (2015) 711e718.
- Gerwin R., Botulinum toxin treatment of myofascial pain: a critical review of the literature, Curr. Pain Headache Rep. 16 (2012) 413e422.
- Gleitz M., K. Hornig, Trigger points-diagnosis and treatment concepts with special reference to extracorporeal shockwaves, Orthopade 41 (2012) 113e125.
- Gleitz M., Shockwave Therapy in Practice: Myofascial Syndrome and Trigger Points, Level 10 Book, first ed., 2011. Germany.
- Grine, F. E. (2004). Regional Human Anatomy: A Laboratory Workbook for Use with Models and Prosections: McGraw-Hill Higher Education.
- Gür, I. Koca, H. Karagüllü, O. Altindag, E. Madenci, A. Tutoglu, A. Boyaci, M. Isik, Comparison of the effectiveness of two different extracorporeal shock wave therapy regimens in the treatment of patients with myofascial pain syndrome, Arch. Rheumatol. 29 (2014) 186e193.
- Haas, J. G. (2010). Dance anatomy. In: Human kinetics Champaign, IL.
- Hall, S. J. (2003). Basic biomechanics: McGraw-Hill Companies.
- Hallam, E. (2008). The Anatomy Museum: Death and the Body Displayed: Reaktion Books, Limited.
- Hammer, D.S.; Rupp, S.; Ensslin, S.; Kohn, D.; Seil, R. Extracorporeal shock wave therapy in patients with tennis elbow and painful heel. Arch. Orthop. Trauma Surg. 2000, 120, 304–307.].
- Hansen, D., & Kennelly, S. (2018). Plyometric Anatomy: Human Kinetics, Incorporated.
- Harris, G., Bou-Haidar, P., & Harris, C. (2013). Adhesive Capsulitis: Review of Imaging and Treatment: Blackwell Pub. Asia.
- Hausdorf J., M.A. Lemmens, K.D. Heck, N. Grolms, H. Korr, S. Kertschanska, H.W. Steinbusch, C. Schmitz, M. Maier, Selective loss of unmyelinated nerve fibers after extracorporeal shockwave application to the musculoskeletal system, Neuroscience 155 (2008) 138e144.
- Healing, G. (2018a). Reversing Adhesive Capsulitis The Raw Vegan Detoxification & Regeneration Workbook for Curing Patients: Healing You.
- Healing, G. (2018b). Reversing Frozen Shoulder The Raw Vegan Detoxification & Regeneration Workbook for Curing Patients: Healing You.

- 1- Health, K., & Education, S. (1999). Overcoming Frozen Shoulder: Krames Health & Safety Education.
- Herrmann, S. (2016). Shoulder biomechanics. In Reverse shoulder arthroplasty (pp. 21-30): Springer.
- Heymsfield, S. B., Peterson, C. M., Thomas, D. M., Heo, M., Schuna Jr, J. M., Hong, S., & Choi, W. J. (2014). Scaling of adult body weight to height across sex and race/ethnic groups: relevance to BMI. *100(6)*, 1455-1461.
- Hodge, S. D., & Education, A. L. (2006). *Anatomy for Litigators: ALI ABA*.
- Hoffmeister, E. (2016). *Review Explores Primary Frozen Shoulder: Lippincott Williams & Wilkins*.
- Hong C.Z., Lidocaine injections versus dry needling to myofascial trigger point. The importance of the local twitch response, *Am. J. Phys. Med. Rehabil.* 73 (1994) 256e263.
- Hong, Y., & Bartlett, R. (2008). *Routledge Handbook of Biomechanics and Human Movement Science: Taylor & Francis*.
- Hsiao, C.-C.; Huang, W.-H.; Cheng, K.-H.; Lee, C.-T. Low-Energy Extracorporeal Shock Wave Therapy Ameliorates Kidney Function in Diabetic Nephropathy. *Oxid. Med. Cell. Longev.* 2019, 2019, 1–12].
- Hsu, J. E., Anakwenze, O. A., Warrender, W. J., Abboud, J. A. & surgery, e. (2011). Current review of adhesive capsulitis. *20(3)*, 502-514.
- Iazzetti, G., & Rigutti, E. (2005). *Atlas of Anatomy: Taj Books*.
- Imamura M., Cassius D.A., F. Fregni, Fibromyalgia: from treatment to rehabilitation, *Eur. J. Pain* 3 (2009) 117e122.
- Ims, I. (2018). *Physiotherapy Treatment Illustrated for Frozen Shoulder (Adhesive Capsulitis): Amazon Digital Services LLC - Kdp Print Us*.
- Jain TK, Sharma NK: The effectiveness of physiotherapeutic interventions in treatment of frozen shoulder/adhesive capsulitis: a systematic review. *J Back Musculoskeletal Rehabil*, 2014, 27: 247–273.].
- Jain, T. K., Sharma, N. K. & Rehabilitation, m. (2014). The effectiveness of physiotherapeutic interventions in treatment of frozen shoulder/adhesive capsulitis: a systematic review. *27(3)*, 247-273.
- Jarmey, C. (2004). *The atlas of musculo-skeletal anatomy: Lotus Publishing*.
- Jeon J.H., Y.J. Jung, J.Y. Lee, J.S. Choi, J.H. Mun, W.Y. Park, C.H. Seo, K.U. Jang, The effect of extracorporeal shock wave therapy on myofascial pain syndrome, *Ann. Rehabil. Med.* 36 (2012) 665e674.
- Ji H.M., H.J. Kim, S.J. Han, Extracorporeal shock wave therapy on myofascial pain syndrome of upper trapezius, *Ann. Rehabil. Med.* 36 (2012) 675e680.
- Johnson, L. L. & research, R. (1987). The shoulder joint. An arthroscopist's perspective of anatomy and pathology. (223), 113-125.
- Kanase SB, Shanmugam S. Effect of Kinesiotaping with Maitland mobilization and Maitland mobilization in management of frozen shoulder. *IJSR.* 2014;3(9):1817-21.
- Kapit, W., & Elson, L. M. (2002). *The Anatomy Coloring Book: Benjamin Cummings*.
- Kim, D. Y., Lee, S. S., Nomkhondorj, O., Cho, M. G., Lee, J. J., Hwang, J. T., & Hong, M. S. (2017). Comparison Between Anterior and Posterior Approaches for Ultrasound-Guided Glenohumeral Steroid Injection in Primary Adhesive Capsulitis: Lippincott, Williams & Wilkins.
- Kim, H. J., Yoo, J. J., Kwak, H. S., Jeong, H. J., & Kim, M. N. (2017). *Adhesive Capsulitis of the Hip: Sage (UK) Limited*.

- Koca, A. Boyaci, A new insight into the management of myofascial pain syndrome, *Gaziantep Med. J.* 20 (2014) 107e112.
- Kolber, M. J., & Hanney, W. J. (2012). The reliability and concurrent validity of shoulder mobility measurements using a digital inclinometer and goniometer: a technical report. 7(3), 306.
- Kolber, M. J., Fuller, C., Marshall, J., Wright, A., Hanney, W. J. J. P. t., & practice. (2012). The reliability and concurrent validity of scapular plane shoulder elevation measurements using a digital inclinometer and goniometer. 28(2), 161-168.
- Kraus M., Reinhart E., Krause H., Reuther J., Low energy of extracorporeal shockwave therapy (ESWT) for treatment of myogelosis of the master muscle, *Mund Kiefer Gesichtschir* 3 (1999) 20e23.
- Kristian, T. E., & fakultet, U. I. (2010). Adhesive Capsulitis, Hydrodilatation and Some Aspect of Validity Regarding Shoulder Assessments: Faculty of Medicine, University of Oslo.
- Kruse R.A., J.A. Christiansen, Thermographic imaging of myofascial trigger points: a follow-up study, *Arch. Phys. Med. Rehabil.* 73 (1992) 819e823.
- Kumar A, Kumar S, Aggarwal A, Kumar R, Das PG. Effectiveness of Maitland Techniques in idiopathic shoulder adhesive capsulitis. *Int Scholar Res Notices.* 2012; 2012.
- Kuwiboonsilp, W., Mahidon, M., & Therapy, M. M. (2014). Immediate Effect of Muscle Energy and Mobilization Techniques on External Rotation Angle in Shoulder Adhesive Capsulitis Condition.
- Kvarstein, G. (2015). Frozen Shoulder and Corticosteroids—still a Need for Needles? : Lippincott Williams & Wilkins, Incorporated.
- Lavelle E.D., W. Lavelle, H.S. Smith, Myofascial trigger points, *Anesthesiol. Clin.* 25 (2007) 841e851.
- Lee, S.; Lee, S.; Jeong, M.; Oh, H.; Lee, K. The effects of extracorporeal shock wave therapy on pain and range of motion in patients with adhesive capsulitis. *J. Phys. Ther. Sci.* 2017, 29, 1907–1909.],
- Levy, O., & Narvani, A. (2011). Biomechanics of the Shoulder and Elbow. In *Orthopedic Sports Medicine* (pp. 145-158): Springer.
- Lho, Y.-M., Ha, E., Cho, C.-H., Song, K.-S., Min, B.-W., Bae, K.-C., . . . surgery, e. (2013). Inflammatory cytokines are overexpressed in the subacromial bursa of frozen shoulder. 22(5), 666-672.
- Limb, D. J. & Textbook, T. (2014). Biomechanics of the Shoulder. 847-864.
- Lin, C.-C., Yang, W.-C., Chen, M.-C., Liu, W.-S., Yang, C.-Y., & Lee, P.-C. *J. A. J. o. K. D.* (2013). Effect of far infrared therapy on arteriovenous fistula maturation: an open-label randomized controlled trial. 62(2), 304-311.
- Liu L., Q.M. Huang, Q.G. Liu, G. Ye, C.Z. Bo, M.J. Chen, P. Li, Effectiveness of dry needling for myofascial trigger points associated with neck and shoulder pain: a systematic review and meta-analysis, *Arch. Phys. Med. Rehabil.* 96 (2015) 944e955.
- Loeffler, B. J., Brown, S. L., Alessandro, D. F., Fleischli, J. E., & Connor, P. M. *J. O.* (2011). Incidence of false positive rotator cuff pathology in MRIs of patients with adhesive capsulitis. 34(5), e81-e87.
- Loew, M.; Daecke, W.; Kusnierczak, D.; Rahmzadeh, M.; Ewerbeck, V. Shock-wave therapy is effective for chronic calcifying tendinitis of the shoulder. *J. Bone Jt. Surgery. Br.* Vol. 1999, 81, 863–867].

- Logan, B. M., McMinn, R. M. H., Singh, D., & Hutchings, R. T. (2004). *McMinn's Color Atlas of Foot and Ankle Anatomy*: Mosby.
- Lorbach, O., Anagnostakos, K., Scherf, C., Seil, R., Kohn, D., Pape, D. J. J. o. s., & surgery, e. (2010). Nonoperative management of adhesive capsulitis of the shoulder: oral cortisone application versus intra-articular cortisone injections. *19*(2), 172-179.
- MacKenzie, M., Cricchio, M., Koczan, B., & Therapists, A. S. o. H. (2003). *Adhesive Capsulitis of the Shoulder*: American Society of Hand Therapists.
- Maria, M. M., Giada, L., Alberto, G., di Sarsina Tommaso, R., Federico, R., Giuseppe, C., & Stefano, Z. (2017). *Shoulder Biomechanics*. In *The Shoulder* (pp. 25-33): Springer.
- Marieb, E. N. (2004). *Laboratory Manual for Anatomy & Physiology*: Pearson Benjamin Cummings.
- Maund, E., Craig, D., Suekarran, S., Neilson, A., Wright, K., Brealey, S., . . . Rangan, A. J. H. T. A. (2012). Management of frozen shoulder: a systematic review and cost-effectiveness analysis. *16*(11), 1.
- McFarland, E. G. (2011). *Examination of the Shoulder: The Complete Guide*: Thieme.
- McKenzie, D., & Richardson, M. (2018). Risk, incidence, and outcomes of postoperative frozen shoulder.
- Merolla, G., Cerciello, S., Chillemi, C., Paladini, P., De Santis, E., Porcellini, G. J. & traumatology. (2015). Multidirectional instability of the shoulder: biomechanics, clinical presentation, and treatment strategies. *25*(6), 975-985.